

# Transcallosal Vs Transcortical Approach to Thalamic Tumors-an Experience

JUNAID KHAN, MUHAMMAD KHALID\* ANISA KALSOOM\*\*

## ABSTRACT

**Objective:** To compare transcallosal approach with conventional transcortical approaches to thalamic tumors.

**Study design:** Retrospective analysis.

**Place & duration:** Department of neurosurgery, CMH Rawalpindi. Jul 2005 to Jan 2007.

**Patients and methods:** we reviewed retrospectively all the cases treated for thalamic tumors with surgical intervention with the aim of maximum removal. 9 patients with thalamic tumors were included, out of which 4 were subjected to the transcallosal approach (Group-I), and 5 were operated through transcortical approach (Group-II). CT scan (plain and with contrast) was performed in all patients. Preoperative GCS and neurological status were recorded and compared with postoperative GCS and neurological status between the two study groups. Independent sample T-test was applied to detect the statistical significance of CSF leak, bleeding requiring transfusion and the tumor removal. Mean scores were compared for analysis of statistical significance between the two groups using paired sample T-test using SPSS-10. Descriptive statistics were applied to record the frequency analysis of gender and age of the patients.

**Results:** Out of nine patients operated, 7 (77.8%) were males, 2 (22.2%) were females and mean age being 36.11 years (SD 16.8). 4 (44.4%) were operated through transcallosal approach and the remaining 5 (55.6%) through transcortical route. A significant improvement in GCS and cognitive status of the patients was observed following transcallosal approach. Motor and sensory improvement was also noticed in patients falling in Group-I, but it did not remain statistically significant. The results remained uncomparable between the two groups as far as the incidence of CSF leak and bleeding requiring transfusion were concerned, ( $P = 0.193$  and  $0.193$ , respectively) but the incidence of seizures in Group-II was significant. The difference between tumor removal remained quite significant ( $P = 0.010$ ). Only one international reference is documented in world literature and this is the first publication in Pakistan to best of my knowledge.

**Conclusion:** Transcallosal approach in patients with tumors confining to thalamus is least hazardous with minimal neurological morbidity and mortality.

**Key words:** Thalamic tumors, transcallosal approach, transcortical approach.

---

## INTRODUCTION

Thalamic tumors comprise 1-5% of all brain tumors<sup>1</sup>. Recent improvements in the therapeutic approaches and surgical techniques have allowed a more accurate approach to these lesions and reduction in morbidity and mortality.

## PATIENTS & METHODS

patients of all ages and both gender were included in the study. only those patients with thalamic lesions having significant intraventricular extension were excluded from the study. 9 patients with thalamic tumors were included, out of which 4 were subjected to

the transcallosal approach (Group-I), and 5 were operated through transcortical approach (Group-II). CT scan (plain and with contrast) was performed in all patients. Preoperative GCS and neurological status were recorded and compared with postoperative GCS and neurological status between the two study groups. Independent sample T-test was applied to detect the statistical significance of CSF leak, bleeding requiring transfusion and the tumor removal. Mean scores were compared for analysis of statistical significance between the two groups using paired sample T-test using SPSS-10. Descriptive statistics were applied to record the frequency analysis of gender and age of the patients.

-----  
*Classified Neurosurgeon, Combined Military Hospital, Peshawar. E-mail: junaidneuro@hotmail.com*

*\* GIZ Deutsche Gesellschaft fuer Internationale Zusammenarbeit GmbH, F7/4, S55, H23, Islamabad, Pakistan*

*\*\*Classified Radiologist, Fauji Foundation Hospital Rawalpindi*

Fig 1: Gender breakdown of the two study groups

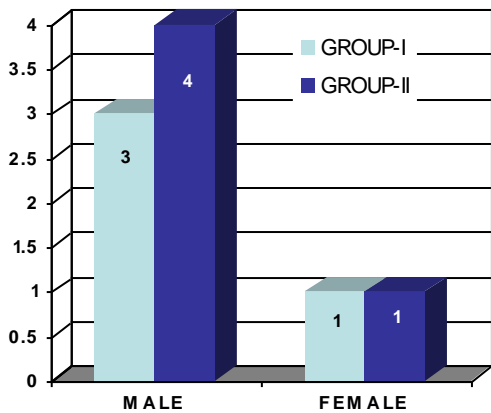
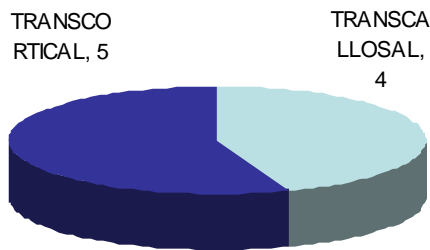


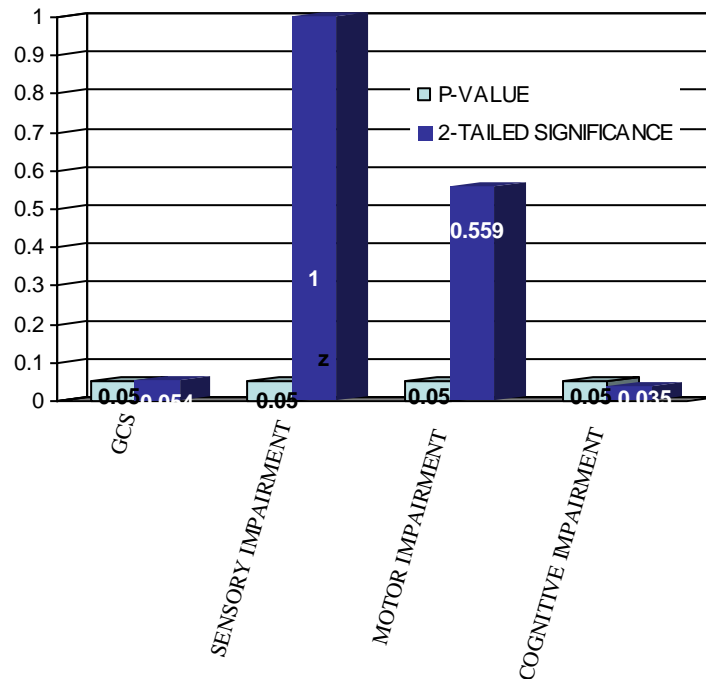
Fig 2: Number of patients in two study groups



## RESULTS

Out of nine patients operated, 7 (77.8%) were males, 2 (22.2%) were females and mean age being 36.11 years (SD 16.8). 4 (44.4%) were operated through transcallosal approach and the remaining 5 (55.6%) through transcortical route. A significant improvement in GCS and cognitive status of the patients was observed following transcallosal approach. Motor and sensory improvement was also noticed in patients falling in Group-I, but it did not remain statistically significant. The results remained uncomparable between the two groups as far as the incidence of CSF leak and bleeding requiring transfusion were concerned, ( $P = 0.193$  and  $0.193$ , respectively). 2 patients operated via transcortical approach had seizures and 2 developed partial hemianopia not seen in patients operated transcallosally. The difference between tumor removal remained quite significant ( $P = 0.010$ ).

Fig 3: Statistical significance of the outcome variables



## DISCUSION

Thalamic Tumours are uncommon, and although gross total removal(GTR) is a prospective goal, its interest is debated because the thalamus constitutes a highly functional region.the relation of choice of surgical approach, achievability of GTR, and operative morbidity to the anatomic location has received little attention in the medical literature<sup>2</sup>. The management of thalamic gliomas is extremely variable, ranging from radical excision to more conservative therapy such as a endoscopic biopsy and radiation<sup>3</sup> we confined our study to tumours involving the medial thalamus and adopted transcallosal approach for removal as suggested by other international studies<sup>4</sup> similarly for posteriorly situated midline lesions a posterior interhemispheric approach is advocated<sup>5</sup> however the tumours with significant exophytic growth into the ventricles are best approached via parietal transcortical transventricular approach<sup>6</sup> the topographic anatomy and morphometry of the fornix is important for standardizing the transcallosal interforncial approach and avoiding memory disturbances<sup>7</sup>.one of the 4 patients in Group-I had hydrocephalus which resolved after tumour removal but preoperative shunting was not done as it could lead to neurological deterioration<sup>8</sup> all of our cases were confined to unilateral thalamus therefore behavioural syptoms were not predominating as involvement of both thalami can lead to significant mood and behavioural changes<sup>9,10</sup> a multitude of different diseases can result in thalamic lesions<sup>11</sup> in our series all were gliomas whereas the overall incidence of low grade gliomas in thalamic region is 17%<sup>12</sup>.In both the groups microscope was used after opening the dura.Gross total resection was done in cases via transcallosal approach while subtotal resection was achieved through transcortical approach , there are studies in which only biopsy followed by radiation has been done<sup>13</sup> CT scan was done in all cases preoperatively however certain studies recommend both CT scan and MRI<sup>14</sup>. Laser,cusa or steriotaxy was not used as surgical adjunct in our cases as recommended by other studies specially in cases with bilateral thalamic involvement.<sup>15,16</sup>

## CONCLUSION

Keeping the fornix , thalamus, midbrain, and internal cerebral vein intact , with few complication and good outcome, transcallosal interforncial approach is an ideal way to resect medial type of thalamic gliomas. Further studies with a prospective evaluation of larger patient samples are called for in the future.

## REFERENCES

1. Memet M, Ozek, Ugur Ture. Surgical approach to thalamic tumors. *Journ Child's Nervous System* 2004 Feb; 18(8): 450-456
2. Francois Mineo, Fabienne Pichon, Jean-Paul Francke and Patrick Dhellemmes. Surgical resection of thalamic tumors in children approaches and clinical results. *Journ Child's Nervous System* 2007 Jul; 23(7): 753-760
3. Selvapandian S. Endoscopic management of thalamic gliomas. *Minim Invasive Neurosurg*.2006 Aug;49(4):194-6
4. Gong J, Ma ZY, Zhang YQ, Jia G, Xie J. Transcallosal interforncial approach for removing the medial type of thalamic gliomas. *Zhonghua Yi Xue ZA Zhi*. 2005 Jun 1;85(20): 1388-91
5. Chi JH, Lawton MT. Posterior interhemispheric approach: surgical technique, application to vascular lesions, and benefits of gravity.
6. Ishii R, Suzuki Y, Watanabe A, Mouri Y, Ishii N, Yoshii I. Gross total removal of gliomas in the pulvinar and correlative microsurgical anatomy. *Neurol Med Chir(Tokyo)*. 2002 Dec ; 42(12): 536-45
7. Ozer MA, Kayalioglu G, Erturk M. Topographic anatomy of the fornix as a guide for the transcallosal-interforncial approach with special emphasis on sex differences. *Neurol Med Chir (Tokyo)*. 2005 Dec ;45(12):607-12
8. Goel A. Preoperative shunts in thalamic tumours. *Neurol India*. 2007 Mar ; 48: 347-50.
9. A Lagares,M de Toledo, P Gonzalez-Leon, J J Rivas, R D Lobato, A Ramos. A Cabello. Bilateral thalamic gliomas: report of a case with cognitive impairment. *Rev Neurol*; 38 (3):244-6
10. A T Kouyialis, E J Boviatsis, G K Prezerakos, S Korfiatis, D E Sakas. Complex neurobehavioural syndrome due to bilateral thalamic glioma.*Br J Neurosurg* 2004 Oct; 18(5):534-7.
11. J Linn, L-A Hoffmann, A Danek, H Bruckmann. Differential diagnosis of thalamic lesions. *Rofo*. 2007 Mar;179(3):234-245
12. S M Yule, T A H Hide, M Cranney, E Simpson, A Barrett. Low grade astrocytomas in the west of Scotland 1987-96: treatment, outcome, and cognitive functioning. *Arch Dis Child* 2001;84:61-64
13. Di Rocco C, Iannelli A. Bilateral thalamic tumours in children. *Childs Nerv Syst*. 2002 Aug;18(8):440-4
14. Colosimo C, Di Lella GM, Tartaglione T, Riccardi B. Neuroimaging of thalamic tumours in children. *Childs Nerv Syst*; 2002 Aug;18(8):426-39
15. Prakash B. Surgical approach to large thalamic gliomas.*Acta Neurochir(wien)*. 1985;74(3-4):100-4
16. Gallina P, Francescon P, Cavedon C, Casamassima F, Mungal R, Perrini P, Russo S, Di Lorenzo N. Steriotactic interstitial radiosurgery with a miniature X-ray device in the minimally invasive treatment of selected tumours in the thalamus and basal ganglia. *Steriotact Funct Neurosurg*.2002;79(3-4):202-13

